


# TOPICS IN MAMMOGRAPHY



## UNIT 1 MAMMOGRAPHIC POSITIONING, BASIC & ADVANCED



JEANETTE R. JOYCE, BFA, RT(R)(M)

COPYRIGHT 2011

## MISSION STATEMENT

It is my goal to provide the mammographer with informative self-study units on breast radiography. Through extensive research, I have compiled interesting and challenging information for today's mammographer. This unit of study is intended to provide the mammographer with an explanation of proper breast positioning during mammography. The mammographer will be introduced to the basic screening projections, as well as the advanced diagnostic projections. The mammographer will learn the value of each projection and be able to identify those situations when supplemental views are useful in breast imaging. The switch from analog to digital mammography will also be discussed as well as the differences encountered in patient positioning. Continuing education enables the mammographer to deliver improved, comprehensive patient care.

*Do not let any unwholesome talk come out of your mouths,  
but only what is helpful for building others up according to their needs,  
that it may benefit those who listen.*

Ephesians 4:29

## COURSE CREDIT

AHRA (The Association for Medical Imaging Management) has approved this post-test for \_\_\_\_ Category A Continuing Education Credits. AHRA is a Recognized Continuing Education Evaluation Mechanism (RCEEM) and has been approved by the ARRT to grant Category A CE credit.

**THE POST-TEST MUST BE COMPLETED AND RETURNED WITHIN TWO YEARS OF PURCHASE.**

**RadComm, Inc.  
20 Rancho Verde  
Tijeras, NM 87059  
(888) 497-2923  
FAX (505) 286-7851**

**To order additional tests for this course or other available courses, visit our website at:  
[www.radcomm.net](http://www.radcomm.net)**

## PERSONAL PROFILE

Jeanette R. Joyce is the founder of RadComm, Inc., a company dedicated to providing continuing education to mammography technologists. In her role as a breast imaging consultant and breast health educator, she has traveled the country instructing fellow mammographers in the fine art of mammography. She has been a registered radiologic technologist (ARRT) since 1975 and received certification in mammography in 1992. She holds a bachelor's degree from Mundelein College (of Loyola University), Chicago. She is a member of the New Mexico Society of Radiologic Technologists (NMSRT). Jeanette was diagnosed with breast cancer in 1998 on an annual screening mammogram at the age of 42 and realizes that knowledge of the disease is our most important weapon.

## LEARNING OBJECTIVES

Upon successful completion of this unit, the radiographer will be able to:

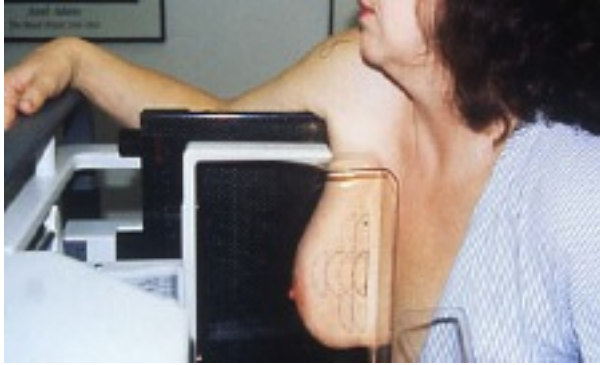1. Identify the primary role of mammography and the group of women to whom it is targeted.
2. Discuss why improper positioning is the primary cause of image failure.
3. Explain how mammography has been proven as an effective method in the detection of early breast cancer.
4. Discuss why the Craniocaudal (CC) and the Mediolateral Oblique (MLO) views were chosen as the international standard views in screening mammography.
5. Distinguish between screening mammography and diagnostic mammography.
6. Describe the task of the mammographer when a patient presents with a palpable lump.
7. Recognize when adequate compression has been applied to the breast.
8. Identify the mobile and fixed borders of the breast.
9. Explain how the mobile and fixed borders of the breast influence positioning techniques.
10. Describe the American College of Radiology's views regarding the importance of the nipple in profile in mammographic positioning.
11. Determine the correct-sized film to adequately image the patient.
12. Review the process for using multiple overlapping films on patients with very large breasts.
13. Describe the operation of the Automatic Exposure Control (AEC) and identify the area of the breast for best placement.
14. Identify situations when a manual technique is necessary in mammographic positioning.
15. Describe the normal variants of breast tissue density.
16. Identify common positioning artifacts in mammography.
17. Explain the importance of elevating the inframammary fold for the Craniocaudal (CC) view.
18. Describe the appearance of the pectoralis muscle on the Craniocaudal (CC) view and cite how often this muscle is visualized on the correctly positioned image.
19. Explain how the Posterior Nipple Line (PNL) measurement is taken.
20. Determine the correct angle of the film holder to place it parallel to the pectoralis muscle.
21. Describe what is meant by the term, "up and out maneuver" and describe its significance in positioning for the Mediolateral Oblique (MLO) view.
22. List the criteria for evaluating the Craniocaudal (CC) and the Mediolateral Oblique (MLO) images.
23. Identify situations when an Exaggerated Craniocaudal Lateral (XCCL) may be useful and describe those areas that are best visualized on this view.

# Unit 1 - MAMMOGRAPHIC POSITIONING, BASIC AND ADVANCED

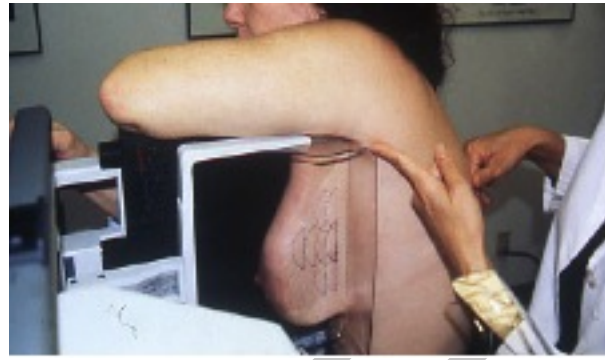## COURSE OUTLINE

- I. Overview
- II. Importance of Proper Positioning
- III. Mammography: Screening VS Diagnostic
  - A. Guidelines for screening mammography
  - B. Guidelines for diagnostic mammography
- IV. Helping the Patient to Relax
- V. MammoPad Breast Cushion
- VI. Breast Mobility
- VII. Nipple in Profile
- VIII. Selecting the Correct-Sized Image Receptor
- IX. Position of the Photocell
- X. Breast Density Considerations
  - A. 4- Category BI-RADS System
- XI. Positioning Artifacts on Mammography
- XII. Basic Standard Views
  - A. Craniocaudal (CC)
    - 1. Posterior Nipple Line (PNL) measurement
    - 2. Criteria for evaluating the CC image
  - B. Mediolateral Oblique (MLO)
    - 1. Criteria for evaluating the MLO image
- XIII. Supplement Views
  - A. Exaggerated Craniocaudal Lateral (XCCL)
  - B. 90° Lateral Views
    - 1. Mediolateral (ML)
    - 2. Lateromedial (LM)
    - 3. Method of Triangulation
  - C. Cleavage (CV)
  - D. Axillary Tail (AT)
  - E. Axilla
  - F. Roll
    - 1. Rolled Lateral (RL)
    - 2. Rolled Medial (RM)
    - 3. Rolled Superior (RS)
    - 4. Rolled Inferior (RI)
  - G. Elevated Craniocaudal (CCE)

## 90-DEGREE LATERAL VIEWS, MEDIOLATERAL (ML) OR LATEROMEDIAL (LM)



90° ML



90° LM

The 90-degree lateral is also referred to as the true lateral or the straight lateral. The Mediolateral and the Lateromedial views are named according to the direction of the x-ray beam. For the Mediolateral view, the beam enters the medial aspect of the breast, transverses the breast, and exits on the lateral side onto the film. The opposite is true for the Lateromedial view. The beam enters laterally, transverses the breast, and exits the medial side of the breast onto the film. When positioning for the ML or LM view, the mammographer does not pull the breast tissue away from the body in a manner parallel to the underlying muscle fibers. For this reason, we are unable to image a maximum amount of breast tissue on this view. The 90° ML or LM should never replace the MLO view.

Dr. G.W. Eklund identifies some distinct advantages of using the Lateromedial (LM) view instead of the Mediolateral (ML) view as long as there is not a lateral lesion of concern. The Lateromedial view places the film holder firmly against the patient's sternum (as far posteriorly as possible) at the immobile medial margin of the breast. The compression paddle is applied to the mobile lateral margin of the breast moving the pectoral muscle and the lateral breast tissue medially along the rib cage and towards the bucky/detector. This technique better visualizes posterior breast tissue because the lateral mobile border of the breast has been utilized.

Typically, the 90-degree lateral is identified not as a screening view, but instead as a troubleshooting view. According to the American College of Radiology, the true lateral is the most commonly used additional view. Now, let us examine those instances when a 90-degree true lateral is helpful:

- The 90° ML or LM provides an image at right angles to the CC view. The CC and the 90-degree lateral are referred to as *orthogonal views* because they are performed at right angles to one another. The 90-degree lateral can be used to locate the exact position of a lesion in a sagittal plane, superior or inferior, when the lesion is seen only on the CC view.
- This view is often necessary to complete the screening study. When inadequate inferior breast compression is observed on the MLO view, it is important to obtain a 90° ML with emphasis on the inferior aspect of the breast. Be certain to include the Inframammary fold on this view to verify that all inferior breast tissue has been imaged.
- The 90° ML or LM is a valuable additional view in patients with an asymmetric, nonpalpable density seen only on the MLO. The ML provides a third imaging plane and will help the radiologist to decide whether the questionable structure is a genuine lesion or only the superimposition of structures. This technique is referred to

as the **triangulation method** and is used to locate lesions. Relative to its distance from the nipple, if the lesion moves down on the Lateral film or is located lower than it was on the Mediolateral Oblique film, the lesion is in the lateral aspect of the breast. However, if the lesion moves up relative to the nipple or is located higher than it was on the Mediolateral Oblique film, the lesion is in the medial aspect of the breast. If no significant change in the location is noted, then the lesion must be located in the central aspect of the breast.

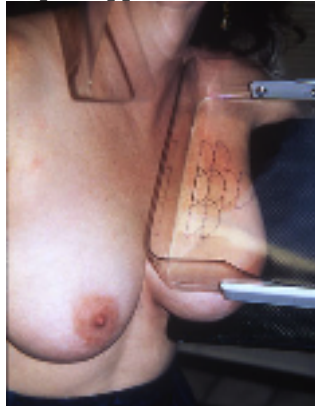**TRIANGULATION**, in summary:

- A **lateral** lesion will move **down** on the 90° lateral (Remember: **DOWN AND OUT**)
- A **medial** lesion will move **up** on the 90° (Remember: **MUFFINS RISE**)
- A central lesion will not move up or down but instead remain in the same position

### STUDY QUESTIONS

1. *In respect to the mobile borders of the breast, what is the distinct advantage in performing a Lateromedial Lateral (LM) as opposed to the more familiar Mediolateral Lateral (ML) view?*
2. *In which direction will a lateral lesion move when comparing the MLO to the 90-degree lateral view?*

### AXILLARY TAIL (AT, 30° Oblique, Upper Outer Quadrant View)



**AXILLARY TAIL**

The Axillary Tail view replaces the Cleopatra view. The Cleopatra view was designed in the era of fixed tabletop technology. Today's technology allows us to rotate the tube head 360° so the Cleopatra view is no longer necessary in mammographic positioning. When performing the Cleopatra view, the patient was forced to lean backwards in an awkward position. It was difficult for the patient to remain stable during the exposure and motion was a common problem. Some facilities continue to practice this position but the ACR recommends that the Axillary Tail view be performed in its place. The mammographer will find that the patient is standing vertically in a more comfortable position and the relationship between the breast tissue and the film has not changed.

The Axillary Tail view visualizes the same area as the Cleopatra view and is much easier for the patient. The Axillary Tail view is intended to visualize the axillary tail region and most of the lateral aspect of the breast. Statistics inform us that approximately 50% of breast cancers are found in the upper outer quadrant of the breast since this is where the majority of glandular tissue is located. The Axillary Tail view is useful because it provides a focal compression view of the axillary tail region.

The Axillary Tail view is a Mediolateral projection. The mammographer must first determine the angle of the axillary tail. Then, the C-arm is rotated until the bucky is parallel to the angle of the patient's axillary tail. Although this view is sometimes referred to as the 30° Oblique, the actual angle of the gantry may vary from 20-45

degrees. This view DOES NOT visualize a lesion in the transverse / axial plane for the purpose of triangulation. This view DOES provide the radiologist with a different projection of the breast tissue. In addition, the mammographer should concentrate the compression paddle on the axillary area, which means the breast will be allowed to drop. 2, 15, 16

### **STUDY QUESTION**

1. *Which view best demonstrates the upper outer quadrant of the breast, that area where the majority of glandular tissue is located and the site of the majority of breast cancers?*

### **AXILLARY TAIL, STEP-BY-STEP INSTRUCTIONS**

- Determine the angle of the axillary tail portion of the breast and place the bucky parallel to that angle. (May vary from 20-45 degrees)
- On the side being examined, the patient should reach her hand to the handle bar.
- The technologist uses two hands to pull the tail of the breast away from the chest wall and onto the bucky surface.
- The patient's shoulder is relaxed with the corner of the bucky in the axilla.
- Compression is applied and the corner of the paddle is under the clavicle.
- Ask the patient to stop breathing.
- Make the exposure.
- Release the compression immediately.

*Areas Visualized: The axillary tail where the majority of the glandular tissue is located, and most of the lateral aspect of the breast.*

## **GLOSSARY OF TERMS**

### **AUTOMATIC EXPOSURE CONTROL**

Also known as the phototiming device. Designed to automatically determine and provide the correct exposure needed to produce an adequate optical density image.

### **AIR GAP TECHNIQUE**

In magnification mammography, this refers to the gap of air between the patient and the film.

### **AP AXILLARY VIEW**

Commonly used for post-mastectomy patients. May also be used to visualize the retromammary space. This is the only view that visualizes the ribs.

### **AXILLARY TAIL VIEW (AT)**

Used to visualize the deep structures of the axilla region and the tail of Spence where the majority of glandular tissue is located.

### **CAUDOCRANIAL VIEW (FROM BELOW, FB)**

Known as the reverse CC. Beam is directed inferior to superior. Helpful in positioning kyphotic patients, male patients, patients with pacemakers and Hickman catheters.

### **CLEAVAGE VIEW (CV)**

Technique used to visualize the tissue in the extreme medial portion of the breast.

### **COMPRESSION**

Essential component of quality mammography. Used to reduce the thickness of the breast, thereby reducing scatter and separating internal structures. Also serves to immobilize the breast and reduce patient dose.

### **CRANIOCAUDAL VIEW (CC)**

One of two standard views that best visualizes the medial and mid breast tissues. Beam is directed superior to inferior.

### **EKLUND MODIFIED COMPRESSION TECHNIQUE (IMPLANT DISPLACED)**

Technique used for women with augmented breasts. These views supplement the standard CC and MLO views.

### **EXAGGERATED CRANIOCAUDAL LATERAL (XCCL)**

This view is used to visualize the lateral breast tissue not seen on the standard CC view.

### **IMMOBILE (FIXED) MARGINS OF THE BREAST**

Identified as the superior and the medial borders of the breast.

### **LATEROMEDIAL LATERAL (TRUE 90° LAT)**

Lateral view used to visualize lesions in the medial aspect of the breast.

### **LATEROMEDIAL OBLIQUE (LMO)**

Known as the reverse MLO. Beam is directed inferolateral to superomedial. Best visualizes lesions in the medial breast. Useful with kyphotic patients.

### **LUMPOGRAM**

Also known as the Elevated Craniocaudal view. Typically used to image lesions in the superior aspect of the breast.

### **MAGNIFICATION TECHNIQUE**

Also known as the air-gap technique. Small focal spot is necessary and the grid is removed. Helpful in examining microcalcifications. Can also be used to better visualize the margins of mass lesions.

### **MEDIOLATERAL LATERAL (TRUE 90° LAT)**

Lateral view used to visualize lesions in the lateral aspect of the breast.

**SELF-ASSESSMENT TEST**  
**UNIT 1: MAMMOGRAPHIC POSITIONING, BASIC AND ADVANCED**

**General Instructions:**

**This self-assessment test contains multiple-choice questions.**

**Please read the directions carefully before answering the questions.**

**Items 1 - 40: Multiple Choice**

Each of the numbered items in this section is followed by answers. Select the **ONE** lettered answer that is **BEST** in each case and fill in the letter with a black marker or pen on the corresponding answer sheet.

- (1) The primary role in screening mammography is to identify early breast cancer among \_\_\_\_\_.
  - (A) asymptomatic women with no signs or symptoms of the disease
  - (B) asymptomatic women over the age of 50
  - (C) symptomatic women with tumors less than 2 mm in size
  - (D) symptomatic women with no evidence of disease spread
  
- (2) The ACR identifies \_\_\_\_\_ as the primary cause for the clinical failure of an image.
  - (A) inadequate processing techniques
  - (B) improper patient positioning
  - (C) sloppy darkroom habits
  - (D) poorly calibrated mammography units
  
- (3) It has been proven that there is a definite reduction in the mortality rate of mammographically screened women for breast cancer by the \_\_\_\_\_.
  - (A) results of ten large international studies dedicated to screening mammography
  - (B) decreasing number of breast cancer deaths
  - (C) results of ten thousand international studies
  - (D) results of tens of thousands U.S. studies
  
- (4) What are the international standard view(s) performed in screening mammography?
  - (A) Craniocaudal (CC) and the Mediolateral Oblique (MLO)
  - (B) Craniocaudal (CC) and the Mediolateral Lateral (ML)
  - (C) Mediolateral Oblique (MLO) only
  - (D) Mediolateral Lateral (ML) only
  
- (5) Mammographic screening routinely includes two views because it provides \_\_\_\_\_.
  - (A) a more cost effective means than three or more views
  - (B) for an easier and quicker method of detection
  - (C) the best opportunity to visualize all breast tissue
  - (D) the best projections based on the patient's comfort